

Case Report

## Surgical Instrument's Tip Fracture During Cataract Surgery

Azlina Mokhtar<sup>1</sup>, Zalifa Zakiah Asnir<sup>2</sup>, Maimunah Abd Munaaim<sup>1</sup>,  
Umi Kalthum Md Noh<sup>3</sup>

<sup>1</sup>Faculty of Medicine and Health Sciences, Universiti Sains Islam Malaysia, Persiaran Ilmu  
Bandar Baru Nilai, 71800 Nilai, Negeri Sembilan Malaysia.

<sup>2</sup>Ophthalmology Department Hospital Ampang, Jalan Pandan Mewah 68000 Ampang,  
Selangor Malaysia.

<sup>3</sup>Sunway Medical Centre, No.5, Jalan Lagoon Selatan Bandar Sunway, 46150 Petaling  
Jaya, Selangor Malaysia.

Correspondence should be addressed to:

Azlina Mokhtar; [drazlina06@usim.edu.my](mailto:drazlina06@usim.edu.my)

Article Info

Article history:

Received: 19 April 2021

Accepted: 26 July 2021

Published: 1 September 2021

Academic Editor:

Sharifah Najwa Syed Mohamad

Malaysian Journal of Science, Health  
& Technology

MJoSHT2021, Volume 7, Special  
Issue

eISSN: 2601-0003

[https://doi.org/](https://doi.org/10.33102/mjosht.v7iSpecialIssue.182)

10.33102/mjosht.v7iSpecialIssue.182

Copyright © 2021 Mokhtar A. et al.

This is an open access article  
distributed under the Creative  
Commons Attribution 4.0

International License, which permits  
unrestricted use, distribution, and  
reproduction in any medium,  
provided the original work is  
properly cited.

**Abstract— Purpose:** To describe a case of a surgical instrument's tip fracture during cataract surgery. **Method:** Case report. **Results:** We report a case of a 60-year-old gentleman who underwent phacoemulsification of the left eye. It was noted that the tip of the second instrument (lens chopper) was fractured during the last quadrant removal of the opacified lens, which disappeared posteriorly. The surgery was successfully completed, and the intraocular lens appeared stable without posterior capsular rent. An urgent computed tomography scan (CT scan) of orbit was arranged. It showed a round radio opaque foreign body near the lens at the lateral aspect of the left intraocular lens (IOL), measuring approximately 0.3cm. The patient underwent foreign body removal using an intraocular magnet by a vitreoretinal surgeon two days after the phacoemulsification surgery. The patient had an uneventful recovery with a vision of 6/60 pinhole 6/6 at six weeks post operatively. **Conclusion:** Surgical instrument's tip fracture is a known complication during phacoemulsification; however, it was under-reported among surgeons. Careful inspection of all instruments before introducing them to the eye is mandatory, and early identification of this condition during surgery may avoid major complications.

**Keywords—** Cataract, Eye Foreign Bodies, Phacoemulsification, Surgical Instruments

### I. INTRODUCTION

A cataract is known as an opacification of the lens, which usually affects the elderly [1]. It is one of the major causes of blindness around the world [2]. Phacoemulsification cataract surgery is the current standard technique adopted widely for the removal of the cataract. This technique involves the introduction of a small instrument into the eye to facilitate the surgery. Instruments breakage during the phacoemulsification is a rare underreported complication, and unfortunately, may necessitate a second surgery and/or result in possible iatrogenic ocular complications.

### II. CASE

A 60-year-old gentleman underwent elective cataract surgery of the left eye. His visual acuity was counting finger due to the presence of dense cataract. Other ocular assessments were entirely normal. He has an uneventful cataract surgery in his right eye two years ago with good visual recovery. Routine phacoemulsification was performed, utilising the 'divide and conquer' technique to remove the lens nucleus. A second instrument was introduced as per routine surgical steps through the side port wound. During the final removal of the lens nucleus, the surgeon noticed that the tip of the second instrument was incomplete (Fig. 1).

The metal tip was seen floating behind the last piece of the nuclear fragment. The broken second instrument was immediately taken out of the eye, followed by a viscoelastic injection to coat the metal tip and protect the thin posterior capsule. Unfortunately, the small fractured metal tip went underneath the iris and could not be viewed despite a careful search, which prolonged irrigation under the iris. Cataract surgery was completed with a subsequent 3-piece intraocular lens implant in the bag, followed by an intracameral injection of antibiotic. No further complication was encountered afterwards. The patient was informed of the complication, and an orbit CT scan was arranged to locate the missing metal tip.

A small round, radio opaque foreign body at the lateral aspect of the left intraocular lens was seen, measuring approximately 0.3cm (Fig. 2). Successful removal of the metal foreign body was achieved by an intraocular magnet two days after his cataract removal. He had an uneventful recovery with the best-corrected visual acuity of 6/6 two months later. Subsequent careful post-operative assessment reveals neither intense inflammation nor damage to any intraocular structures.




Fig. 1 The broken end of the second instrument's tip (Blue arrow). The neck of the second instrument (white arrow)

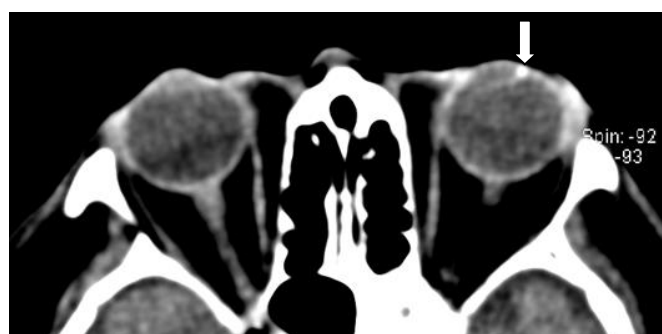


Fig. 2 CT Scan of the orbit showed a round radio opaque foreign body at the lateral aspect of the left intraocular lens, measuring approximately 0.3cm (white arrow)

### III. DISCUSSION

Fractured instrument during phacoemulsification leads to an entrapped intraocular foreign body. This may happen at any point during instrumentation, especially if there is frequent contact between different instruments used

simultaneously in the narrow anterior chamber. Several reports have documented similar occurrences of either fractured second instrument [3-5] or the main phacoemulsification sleeve [3] left in the eye during cataract surgery.

They also reported retained metallic foreign body post phacoemulsification derived from fracture of the instrument during the surgery [7,8]. The retained metallic foreign body was seen on the iris [7,9,10], corneal stromal [9] and anterior chamber [5]. These metallic foreign bodies came from the second instrument, phacoemulsification sleeve and phaco tip [8-12]. In our case, the fracture fragment was from the tip of the second instrument, and this is the first case that reported a foreign body in the bag of the lens.

The second instrument is a useful metal piece that is utilised in different ways during phacoemulsification. It is used as a divider of lens nucleus during manipulation and removal of lens fragment, aiding in protecting capsular damage from phaco-tip touch. After complete sculpting of the lens nucleus, the second instrument can be placed around the nucleus's equator and pulled right through the posterior plate dividing the nucleus into half and quarter. Once the cataract has been divided into four quadrants, the second instrument can be positioned behind a separated segment to pull it out to assist in emulsifying the nucleus. The neck of the second instrument allows protection of the posterior capsule in positive or high vitreous pressure cases.

We noted the fractured tip of the second instrument during manipulation of the nucleus. It was difficult to pull the nucleus close to the phacoemulsification probe due to the missing tip. The surgery was stopped, and the fractured second instrument was carefully removed from the eye. We immediately injected viscoelastic material into the anterior chamber to protect the endothelium and the bag to shield the posterior capsule from the fragmented instrument. Initially, the tip was seen floating in the anterior chamber but subsequently missing behind the iris.

A few case reports describe the challenges faced by surgeons to complete phacoemulsification cataract surgery when there is an intraoperative fracture of instruments [5-6]. Shum et al. described fluctuation of anterior chamber depth as a sign of damaged phacoemulsification sleeve. This leads to reduced efficiency in fragment aspiration. Posterior capsule rent may happen from scratching off a sharp broken tip when there was no viscoelastic to cushion the posterior capsule or coat the metal tip. The thin posterior capsule may tear from the sudden collapse of the anterior chamber, leading to an inadvertent touch of the instrument tip (either the proximal second instrument held by the surgeon or the phaco-probe itself). Post-operatively, inflammation is also an indicator of the possible retained fragment, no matter how small it may be [11,13].

The broken instrument was noted to be fractured at the neck (Fig.1). We believe that the vibration from the oscillation of the phacoemulsification probe, which came in close contact with the second instrument, leads to the latter's weakening and subsequent fracture [8,12]. The definite mechanism remains indistinct. Nazemi et al. postulated that a combination of factors such as manufacturing defect and progressive weakening for inadvertent tip touch led to the fracture of the second instrument [6].

Upon recognising the broken tip of the second instrument, the surgery may still be completed successfully, with intraocular lens implantation at the normal position, as demonstrated in our case. We highlight the importance of careful removal of the broken instrument from the eye and protecting the posterior capsule and corneal endothelium using a dispersive viscoelastic. The operating surgeon must remain calm in this situation and assess the next best step to minimise further complications. The steps taken must also include considering at which stage the surgery has been completed and whether it was better to proceed with nucleus delivery through a bigger wound by converting to extracapsular cataract surgery.

We recommend careful inspection of instruments under a microscope, either by the surgeon or assisting nurse prior to using them. Cleaning and disinfection of the small instrument should be done properly and carefully to ensure the small part is not broken during the process.

#### IV. CONCLUSIONS

The adequate inspection of all instruments and early identification of the problem during the surgery are key for reducing the complication caused by the defective surgical instrument.

#### CONSENT TO PARTICIPATE

Written informed consent was obtained from the patient for the anonymised information published in this article.

#### CONFLICT OF INTERESTS

The authors declare that there is no conflict of interest.

#### ACKNOWLEDGEMENT

The authors would like to thank the Director General of Health Malaysia for permission to publish this paper.

#### REFERENCES

[1] Asbell, P. A., Dualan, I., Mindel, J., Brocks, D., Ahmad, M., & Epstein, S. (2005). Age-related cataract. *The Lancet*, 365(9459), 599-609.

[2] Reddy, S. C., Tajunisah, I., Low, K. P., & Karmila, A. B. (2008). Prevalence of eye diseases and visual impairment in urban population—a study from University of Malaya Medical Centre. *Malaysian family physician: the official journal of the Academy of Family Physicians of Malaysia*, 3(1), 25.

[3] Nazemi, F., Odorcic, S., Braga-Mele, R., & Wong, D. (2008). Second instrument tip breaks during phacoemulsification. *Canadian Journal of Ophthalmology*, 43(6), 702-706.

[4] Varma, D. K., Shaikh, V. M., Hillson, T. R., & Ahmed, I. I. K. (2010). Migration of retained broken chopper tip after phacoemulsification. *Journal of Cataract & Refractive Surgery*, 36(5), 857-860.

[5] Pelosini, L., Richardson, E. C., Goel, R., & Hugkulstone, C. E. (2006). Intraoperative breakage of the mushroom manipulator tip during phacoemulsification. *Eye*, 20(12), 1451-1452.

[6] Shum, J. W., Chan, K. S., Wong, D., & Li, K. K. (2010). Intraoperative fracture of phacoemulsification sleeve. *BMC ophthalmology*, 10(1), 1-4.

[7] Chaudhari, M., Agarwala, N. S., & Nayak, B. K. (2013). Determination of the nature and origin of the metallic foreign particles appearing on the iris after phacoemulsification. *Journal of Cataract & Refractive Surgery*, 39(7), 1008-1010.

[8] Martinez-Toldos, J. J., Elvira, J. C., Hueso, J. R., Artola, A., Mengual, E., Barcelo, A., ... & Martinez-Reina, M. J. (1998). Metallic fragment deposits during phacoemulsification. *Journal of Cataract & Refractive Surgery*, 24(9), 1256-1260.

[9] Dunbar, C. M., Goble, R. R., Gregory, D. W., & Church, W. C. (1995). Intraocular deposition of metallic fragments during phacoemulsification: possible causes and effects. *Eye*, 9(4), 434-436.

[10] Thomas, D., & McLean, C. (2002). Retained fragments in the anterior segment following phacoemulsification surgery. *Eye*, 16(1), 94-95.

[11] Stangos, A. N., Pournaras, C. J., & Petropoulos, I. K. (2005). Occult anterior-chamber metallic fragment post-phacoemulsification masquerading as chronic recalcitrant postoperative inflammation. *American journal of ophthalmology*, 139(3), 541-542.

[12] Davis, P. I., & Mastel, D. (1998). Anterior chamber metal fragments after phacoemulsification surgery. *Journal of Cataract & Refractive Surgery*, 24(6), 810-813.

[13] Yeniad, B., Beginoglu, M., & Ozgun, C. (2010). Missed intraocular foreign body masquerading as intraocular inflammation: two cases. *International ophthalmology*, 30(6), 713-716